

This article was downloaded by: [Daniel Amen]

On: 06 April 2012, At: 18:51

Publisher: Routledge

Informa Ltd Registered in England and Wales Registered Number: 1072954 Registered office: Mortimer House, 37-41 Mortimer Street, London W1T 3JH, UK



## Journal of Psychoactive Drugs

Publication details, including instructions for authors and subscription information:  
<http://www.tandfonline.com/loi/ujpd20>

### High Resolution Brain SPECT Imaging of Marijuana Smokers with AD/HD

Daniel G. Amen<sup>a</sup> & Martin Waugh<sup>b</sup>

<sup>a</sup> The Amen Clinic for Behavioral Medicine, Fairfield, California

<sup>b</sup> Davis, California

Available online: 06 Sep 2011

To cite this article: Daniel G. Amen & Martin Waugh (1998): High Resolution Brain SPECT Imaging of Marijuana Smokers with AD/HD, Journal of Psychoactive Drugs, 30:2, 209-214

To link to this article: <http://dx.doi.org/10.1080/02791072.1998.10399692>

PLEASE SCROLL DOWN FOR ARTICLE

Full terms and conditions of use: <http://www.tandfonline.com/page/terms-and-conditions>

This article may be used for research, teaching, and private study purposes. Any substantial or systematic reproduction, redistribution, reselling, loan, sub-licensing, systematic supply, or distribution in any form to anyone is expressly forbidden.

The publisher does not give any warranty express or implied or make any representation that the contents will be complete or accurate or up to date. The accuracy of any instructions, formulae, and drug doses should be independently verified with primary sources. The publisher shall not be liable for any loss, actions, claims, proceedings, demand, or costs or damages whatsoever or howsoever caused arising directly or indirectly in connection with or arising out of the use of this material.

# High Resolution Brain SPECT Imaging of Marijuana Smokers with AD/HD

Daniel G. Amen, M.D.\* & Martin Waugh, D.O.\*\*



**Abstract**—Marijuana abuse is common among young Americans and even more common among teenagers and adults with attention deficit/hyperactivity disorder (AD/HD). Many teenagers and young adults believe that marijuana is a safe substance to use despite a number of studies demonstrating cognitive impairment with chronic or heavy usage. Brain single photon emission computer tomography (SPECT) imaging is being used increasingly in psychiatry to study underlying functional brain problems, including AD/HD. SPECT provides information on cerebral blood flow and metabolic function. Brain SPECT studies were performed on 30 heavy marijuana users (who had used on at least a weekly basis for a minimum of one year) with AD/HD from an outpatient psychiatric clinic and 10 AD/HD control group subjects matched for age and sex who had never used drugs. The three-dimensional surface images were used in the analysis of the scans, and were blindly interpreted without knowledge of the clinical data. Decreased perfusion in the prefrontal cortex was the only abnormality seen in the AD/HD control group (80%). In the marijuana group, there was a similar decrease in the perfusion of the prefrontal cortex while performing the same concentration task (83%). However, the marijuana group also demonstrated marked decreased activity in the right and left temporal lobes. The severe and moderate ratings were found in the heaviest users, but not necessarily the longest users. This study demonstrates decreased cerebral perfusion in the temporal lobe regions of the brain on SPECT imaging from chronic marijuana usage.

**Keywords**—cerebral SPECT, marijuana, temporal lobe dysfunction

Marijuana use is common among Americans. It is estimated that 67.4 million Americans have tried marijuana, 19.2 million in the past year, and 9.7 million in the past month (Kaplan & Sadock 1995). Many teenagers and young adults believe that marijuana is a safe substance to use despite a number of studies demonstrating cognitive, emotional and social impairment with chronic or heavy usage (Pope & Yurgelun-Todd 1996; Williams, Wellman & Rawlins 1996; Yamada, Kendix & Yamada 1996; Solowij 1995; Spunt et al. 1994; Gold & Slaby 1991; Tunving 1985). Marijuana has also been described as a “gateway” drug by

several authors, with one study reporting that 98% of cocaine users started first with marijuana (Gold 1991). Despite these studies, there is controversy among both the general population and the medical community concerning whether or not marijuana use is harmful (Hall 1995). Legalizing marijuana has been a social/political topic for decades.

Brain single photon emission computer tomography (SPECT) imaging is a nuclear medicine study which may offer the most widely available and widely applicable measure of neuronal behavior (Devous 1995). SPECT measures cerebral blood flow and, indirectly, brain metabolism (Raichle, Grubb & Gado 1976). Brain SPECT imaging is being used increasingly in psychiatry, especially when underlying functional brain problems are suspected (George 1991). SPECT has also been used to study the effects of

\*Medical Director, The Amen Clinic for Behavioral Medicine, Fairfield, California.

\*\*Private practice, Davis, California.

Please address correspondence and reprint requests to Daniel G. Amen, M.D., The Amen Clinic for Behavioral Medicine, 350 Chadbourne Road, Fairfield, California 94585.

drug abuse on the brain (Kao, Wang & Yeh 1994; Mena et al. 1994; Schwartz et al. 1993; Shih 1993; Strickland & Mena 1993; Kubota et al. 1983). Specifically, SPECT has been used to study both the short-term and long-term effects of marijuana on the brain (Matthew & Wilson 1991; Matthew, Wilson & Tant 1989; Matthew, Burger & Tant 1986). These studies reported that inexperienced marijuana smokers had an acute decrease in cerebral blood flow, and that chronic marijuana users had overall decreased perfusion when compared to a normal control group.

In performing a number of SPECT studies for clinical indications on marijuana abusers from a general psychiatric population, the authors noticed temporal lobe hypoperfusion which was not mentioned in the above studies, most likely because of the lower sensitivity of SPECT resolution five to 10 years ago. It was unclear if the temporal lobe hypoperfusion was related to marijuana use or to other underlying neurological or psychiatric conditions. The authors felt that continued study of cerebral perfusion in marijuana users could add information to the ongoing debate on the effects of marijuana on the brain.

The comorbid diagnosis of attention deficit/hyperactivity disorder (AD/HD) was used in this study for three reasons. First, the functional brain imaging studies of AD/HD have not reported temporal lobe abnormalities (Sieg et al. 1995; Ernst et al. 1994; Mann, Lubar & Zimmerman 1992; Lubar 1991; Lou, Henriksen & Bruhn 1990, 1984; Zametkin, Nordahl & Gross 1990). Also, utilizing a control group with the same diagnoses eliminates the uncertainty of contaminating the findings by comparing them to a general psychiatric control group. Even a normal control group adds an element of uncertainty because so many marijuana users have additional diagnoses; comparison to a population with the same diagnosis should provide useful information. Finally, 52% of AD/HD sufferers have been reported to have problems with substance abuse—many of them with marijuana abuse (Biederman et al. 1995).

## METHOD

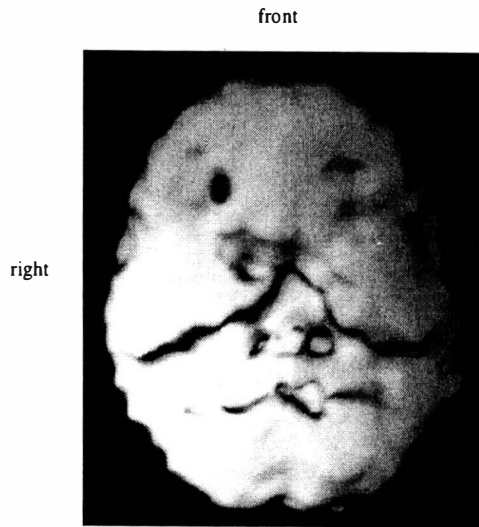
Thirty teenage and adult right-handed marijuana smokers from an outpatient psychiatric clinic (who had used on at least a weekly basis for a minimum of one year) and who had been diagnosed with AD/HD, and 10 control group subjects also diagnosed with AD/HD (matched for age, sex and handedness) who had never abused any drugs consented to having a brain SPECT study as part of their initial work-up. Age range for the marijuana group was 16 to 45 (average age was 28), with 22 males and eight females. Age range for the control group was 16 to 46 (average age was 30), with seven males and three females. In the marijuana group, marijuana was the primary drug of choice. The interval between the most recent marijuana use and the SPECT scan ranged from 24 hours to two years. Two-thirds of the group had used within the six months before the study. Anyone

who met the *DSM-III-R* diagnostic criteria for alcohol or other substance abuse or dependence was eliminated from the study. Marijuana usage ranged from daily to weekly, and from one year to 22 years. Recent toxicology was not obtained on most subjects, and the authors relied on patient and family histories. Diagnoses were made by a board-certified psychiatrist (Dr. Amen) using information from clinical interviews, mental status examinations, and structured interviews utilizing the *DSM-IV* criteria for AD/HD. In addition, Decisionbase (a commercially available, structured *DSM-III-R* computerized interview) was also performed by each of the participants to rule out other psychiatric diagnoses. If there was a disagreement between the findings of Decisionbase and clinical interview, the psychiatrist decided on the final diagnosis utilizing all of the data. In this study the disagreement between Decisionbase and the psychiatric diagnoses was minimal. Three out of the forty patients who were not diagnosed with AD/HD on Decisionbase were diagnosed clinically using the *DSM-IV* criteria. The AD/HD control group reported no drug use during their lifetime. Informed consent for the procedure was obtained for each subject. All subjects were medication-free at the time of the study, and participants reported being free for at least 24 hours from any marijuana use. In addition, patients who were taking stimulant medication for AD/HD were medication-free for at least one week.

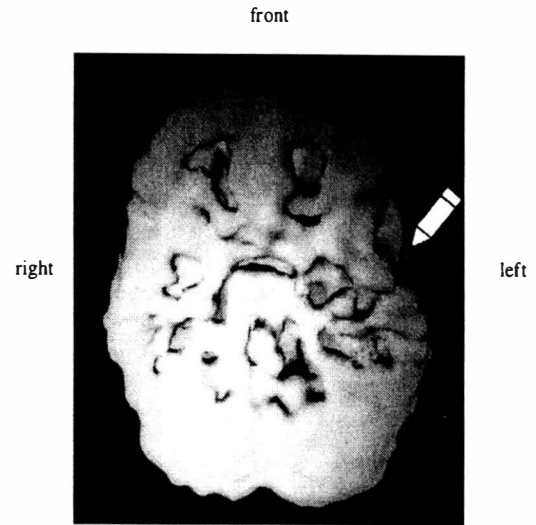
The brain SPECT studies were done in the following manner. The patients were placed in a quiet room and intravenous access was obtained via small-gauge butterfly. The patients remained quiet for five minutes with their eyes open to allow their mental state to equilibrate to the environment. Then each patient performed a standardized continuous performance task (Conner's CPT, developed by Conners and distributed by MHS). The task was performed for five minutes before and 10 minutes after Ceretec (99m Tc hexamethylpropylene amine oxime, HMPAO) was injected through the IV line. A tomographic brain study was performed approximately 30 minutes later using a high-resolution Picker Prism 3000 gamma camera with fan beam collimators. Data were acquired in 128 X 128 matrices. One hundred twenty images with three degrees separation spanning 360 degrees rotation were obtained. The data were prefiltered using a Ramp filter with a high cutoff. Attenuation correction was performed using a linear method. Coronal, sagittal and transaxial tomographs were reconstructed with a slice thickness of approximately 9 mm. The transaxial tomographs were parallel to the orbitalmeatal line. The tomographs obtained with HMPAO SPECT are those of relative blood flow, as opposed to absolute quantification of blood flow; they were displayed using a standardized color scale. The transaxial images were then used to produce three-dimensional surface images using a standard Picker surface projection technique. A threshold of 55% of the maximal pixel count within the

**FIGURE 1**

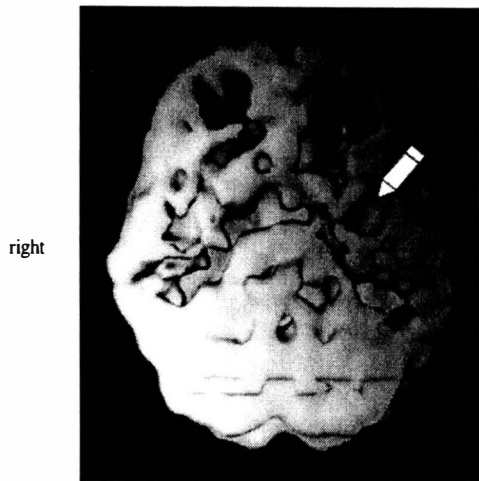
Brain SPECT Studies of Marijuana Abusers and Nonusers



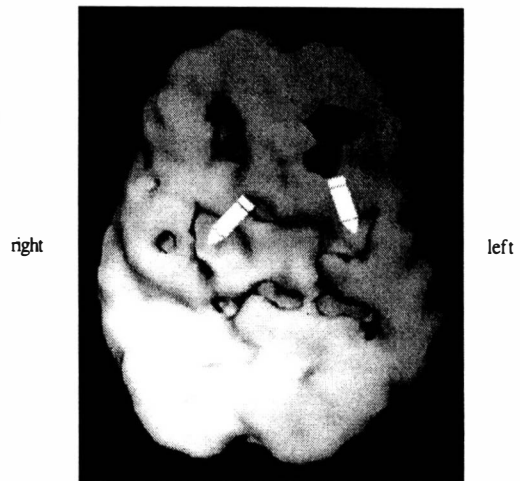
Normal study; notice smooth, full, even surface



16-year-old male with two-year history of daily usage; notice marked decreased perfusion, especially in temporal lobes



44-year-old male with 12-year history of daily usage; notice marked decreased activity



32-year-old female with a 12-year history of mostly weekend usage; notice areas of decreased activity in medial temporal lobes

3D undersurface view, looking at the most active 45% of brain activity

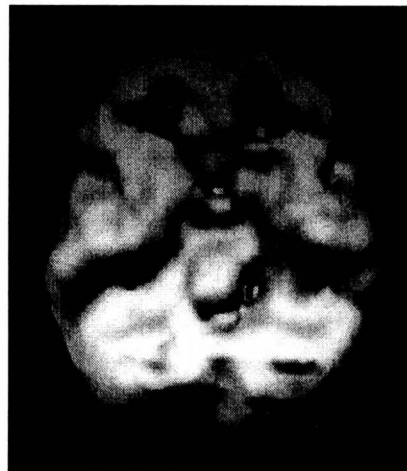
brain was used. The surface image displays the pixels on the outer surface of the brain that are at this threshold level. Areas of uptake less than the chosen threshold value appear as defects. The three-dimensional surface images were used in the analysis because, when using qualitative visual inspection, they show the small cortical peripheral defects more clearly than conventional tomographic images (Tumeth et al. 1990). The images were blindly interpreted without knowledge of the clinical data. Each three-dimensional image was rotated around the horizontal and vertical plane to evaluate the top, lateral and undersurface of the brain. The three-dimensional images were interpreted as either normal or abnormal. The degree of abnormality was classified as unilateral or bilateral, and mild, moderate or severe. Reading scans through visual inspection was felt to be appropriate in this setting. Clinically, brain SPECT studies are read through visual inspection of the nuclear physician; several other studies have reported using visual inspection, stating that the informed human visual cortex is the preferred instrument for clinical analysis of these scans (Schuckit et al. 1995; Ketter et al. 1994; O'Tuama & Treves 1993).

## RESULTS

The only abnormality seen in the AD/HD control group was decreased perfusion in the prefrontal cortex in eight of the 10 subjects. Five showed a decrease in the left prefrontal cortex only, while two showed decreased activity in both the left and right prefrontal cortex, and one showed decreased activity only on the right side. No other surface abnormalities were noted. The decreased activity in the prefrontal cortex was rated as severe in three subjects, moderate in two, and mild in three.

A similar incidence of prefrontal cortex hypoperfusion was noted for 25 of the 30 marijuana users (83%). Eighteen showed decreased activity in the left prefrontal cortex only, while five showed decreased activity in both the left and right prefrontal cortex, and two showed decreased activity only on the right side. There were more severe and moderate ratings in this part of the brain in the marijuana group. Twelve were rated as severe, eight moderate and five mild. In addition, 16 showed bilateral areas of defects or decreased perfusion in the temporal lobes, while eight showed unilateral areas of defects or decreased perfusion in the temporal lobes (five on the left, three on the right). Of the 24 with defects in the temporal lobes, five (21%) were rated as severe, seven (29%) were rated as moderate, and 12 (50%) were rated as mild. The severe and moderate ratings were in the heaviest users (whose use was greater than four times a week in the past year), but not necessarily the longest-term users. One teenager who had been a daily user for two years showed some of the most profound temporal lobe hypoperfusion among the group. Two patients had mild

**FIGURE 2**  
AD/HD Control



Notice decreased prefrontal cortex with normal temporal lobe activity

defects in the left parietal area and three had defects in the occipital area (two on the left, one on the right). No other areas of significant defects or decreased perfusion were noted. The time away from marijuana use also seemed to make a difference. Even though deficits were found in the patients who had not used marijuana in six months or more, they were more likely to be classified in the mild to moderate group rather than the severe group; only one of them was in the severe group. Clinically, four patients had an amotivational syndrome (severe lack of interest, motivation and energy). All four had decreased perfusion in their temporal lobes; three were rated as severe, one as moderate.

Figure 1 shows a normal three-dimensional surface view of the brain, and representative three-dimensional images of surface views of three brains affected by marijuana usage. Figure 2 shows a view of a control brain.

## DISCUSSION

This study is consistent with previous SPECT findings in AD/HD cases, showing decreased perfusion in the prefrontal cortex, especially on the left side (Sieg et al. 1995; Amen, Paldi & Thisted 1993; Lou, Henriksen & Bruhn 1990, 1984). The three-dimensional surface renderings give particularly elegant views of brain surface activity showing this abnormality. Prefrontal cortex functions include attention span, concentration, judgment, activity

level, critical thinking and impulse control (Luria 1969). It is not surprising, therefore, to see prefrontal cortex hypoperfusion in a significant majority of the AD/HD cases. With hypoperfusion in the prefrontal cortex there may be a loss of inhibition normally exerted by this part of the brain, resulting in hyperactive, impulsive and inattentive behaviors.

This study is also consistent with previous studies (Matthew, Burger & Tant 1986) in demonstrating that frequent, long-term marijuana use has the potential to change the perfusion pattern of the brain. As opposed to that study, which showed global hypoperfusion, our study found local hypoperfusion in the temporal lobes. This may be accounted for by the increased sophistication of the imaging camera used. Abnormal activity in the temporal lobes has been associated with memory, learning and motivational

problems (Kandel & Schwartz 1985), common complaints of teenagers and adults who chronically abuse marijuana. The symptoms of amotivational syndrome—such as apathy, poor attention span, lethargy, social withdrawal, and loss of interest in achievement—have been attributed to marijuana abuse for thousands of years (Kaplan & Sadock 1995). The authors speculate that it may be related to temporal lobe dysfunction secondary to heavy marijuana use. The teenage male in the study who had used daily for two years and had severe hypoperfusion in the temporal lobes had symptoms consistent with amotivational syndrome and had dropped out of school in the eleventh grade.

In conclusion, this study demonstrates decreased cerebral perfusion in the temporal lobe regions of the brain on brain SPECT imaging from chronic marijuana usage.

## REFERENCES

- Amen, D.G.; Paldi, J.H. & Thisted, R. 1993. Evaluating ADHD with Brain SPECT Imaging. (letter) *Journal of Child and Adolescent Psychiatry* 32:1080-81.
- Biederman, J.; Wilens, T.; Mick, E.; Milberger, S.; Spencer, T.J. & Faraone, S.V. 1995. Psychoactive substance use disorders in adults with attention deficit hyperactivity disorder (ADHD): Effects of ADHD and psychiatric comorbidity. *American Journal of Psychiatry* 152 (11): 1652-8.
- Devous Sr., M.D. 1995. SPECT functional brain imaging. In: E.L. Kramer & J.J. Sanger (Eds.) *Clinical SPECT Imaging*. New York: Raven Press.
- Ernst, M.; Liebenauer, L.L.; King, A.C.; Fitzgerald, G.A.; Cohen, R.M. & Zametkin, A.J. 1994. Reduced brain metabolism in hyperactive girls. *Journal of the American Academy of Child and Adolescent Psychiatry* 33 (6): 858-68.
- George, M.S. 1991. *Neuroactivation and Neuroimaging with SPECT*. New York, Berlin & Heidelberg: Springer-Verlag.
- Gold, M.S. 1991. *The Good News About Drugs and Alcohol*. New York: Villard Books.
- Gold, M.S. & Slaby, A.E. 1991. *Dual Diagnosis in Substance Abuse*. New York: Marcel Decker.
- Hall, W. 1995. The health risks of cannabis. *Australian Family Physician* 24(7):1237-40.
- Kandel, E.R. & Schwartz, J.H. 1985. *Principles of Neuroscience*. New York: Elsevier.
- Kao, C.H.; Wang, S.J. & Yeh, S.H. 1994. Presentation of regional cerebral blood flow in amphetamine abusers by 99Tcm-HMPAO brain SPECT. *Nuclear Medicine Communications* 15 (2): 94-98.
- Kaplan, H.I. & Sadock, B.J. 1995. *Comprehensive Textbook of Psychiatry*. Sixth Ed. Baltimore: Williams and Wilkins.
- Ketter, T.A.; George, M.S.; Ring, H.A.; Pazzaglia, P.; Marangell, L.; Kimbrell, T.A. & Post, R.M. 1994. Primary mood disorders: Structural and resting functional studies. *Psychiatric Annals* 24:637-42.
- Kubota, K.; Yamaguchi, T.; Abe, Y.; Fujiwara, T.; Hatazawa, J. & Matsuzawa, T. 1983. Effects of smoking on cerebral blood flow in neurologically normal subjects. *Stroke* 14:720-24.
- Lou, H.C.; Henriksen, L. & Bruhn, P. 1990. Focal cerebral dysfunction in developmental learning disabilities. *Lancet* 335 (8680): 8-11.
- Lou, H.C.; Henriksen, L. & Bruhn, P. 1984. Focal cerebral hypoperfusion in children with dysphasia and/or attention deficit disorder. *Archives of Neurology* 41 (8): 825-9.
- Lubar, J.F. 1991. Discourse on the development of EEG diagnostics and biofeedback for attention deficit-hyperactivity disorders. *Biofeedback and Self-Regulation* 16:201-25.
- Luria, A.R. 1969. Frontal lobe syndromes. In: A. Vincker & G. Bruyn (Eds.) *Handbook of Clinical Neurology*, Vol. 2. New York: Elsevier, North Holland.
- Mann, C.A.; Lubar, J.F. & Zimmerman, A.W. 1992. Quantitative analysis of EEG in boys with attention deficit-hyperactivity disorder: Controlled study with clinical applications. *Pediatric Neurology* 8:30-36.
- Matthew, R.J. & Wilson, W.H. 1991. Substance abuse and cerebral blood flow. *American Journal of Psychiatry* 148 (3): 292-305.
- Matthew, R.J.; Burger, C. & Tant, S.R. 1986. Regional cerebral blood flow in marijuana smokers. *British Journal of Addiction* 81:567-71.
- Matthew, R.J.; Wilson, W.H. & Tant, S.R. 1989. Acute changes in cerebral blood flow associated with marijuana smoking. *Acta Psychiatrica Scandinavica* 79:118-28.
- Mena, I.; Giombetti, R.J.; Miller, B.L.; Garrett, K.; Villanueva-Meyer, J.; Mody, C. & Goldberg, M.A. 1994. Cerebral blood flow changes with acute cocaine intoxication: Clinical correlations with SPECT, CT, and MRI. In: H. Sorer & R. Rapaka (Eds.) *Imaging Techniques in Medications Development: Preclinical and Clinical Aspects*. NIDA Research Monograph No. 138. Rockville, Maryland: U.S. Department of Health & Human Services.
- O'Tuama, L.A. & Treves, S.T. 1993. Brain single photon emission computed tomography for behavior disorders in children. *Seminars in Nuclear Medicine* 23:255-63.
- Pope, H.G. Jr. & Yurgelun-Todd, D. 1996. The residual cognitive effects of heavy marijuana use in college students. *Journal of the American Medical Association* 275 (7): 521-7.
- Raichle, M.E.; Grubb, R.L. & Gado, M.H. 1976. Correlation between regional cerebral blood flow and oxidative metabolism. *Archives of Neurology* 33:523-26.
- Schuckit, M.A.; Jobst, K.A.; George, M.S.; Van Heertum, R.L. & Mendelson, J.H. 1995. Difficult differential diagnoses in psychiatry: The clinical use of SPECT. *Journal of Clinical Psychiatry* 56:539-42.
- Schwartz, J.A.; Speed, N.M.; Gross, M.D.; Lucey, M.R.; Bazakis, A.M.; Hariharan, M. & Beresford, T.P. 1993. Acute effects of alcohol administration on regional cerebral blood flow: The role of acetate. *Alcoholism, Clinical and Experimental Research* 17 (6): 1119-23.
- Sieg, K.G.; Gaffney, G.R.; Preston, D.F. & Hellings, J.A. 1995. SPECT brain imaging abnormalities in attention deficit hyperactivity disorder. *Clinical Nuclear Medicine* 20 (1): 55-60.
- Shih, W.J. 1993. Volume and surface three-dimensional displays of Tc-99m HMPAO brain SPECT imaging in a chronic hypnosedative abuser. *Clinical Nuclear Medicine* 18 (6): 506-9.

- Solowij, N. 1995. Do cognitive impairments recover following cessation of cannabis use? *Life Sciences* 56 (23-24): 2119-26.
- Spunt, B.; Goldstein, P.; Brownstein, H. & Fendrich, M. 1994. The role of marijuana in homicide. *International Journal of the Addictions* 29 (2): 195-213.
- Strickland, T.L. & Mena, I. 1993. Cerebral perfusion and neuropsychological consequences of chronic cocaine use. *Journal of Neuropsychiatry and Clinical Neuroscience* 5 (4): 419-27.
- Tumeth, S.S.; Nagel, J.S.; English, R.J.; Moore, M. & Holman, B.L. 1990. Cerebral abnormalities in cocaine abusers: Demonstration by SPECT perfusion brain scintigraphy. *Radiology* 176:821-24.
- Tunving, K. 1985. Psychiatric effects of cannabis use. *Psychiatria Scandinia* 72:209-17.
- Williams, J.H.; Wellman, N.A. & Rawlins, J.N. 1996. Cannabis use correlates with schizotypy in healthy people. *Addiction* 91 (6): 869-77.
- Yamada, T.; Kendix, M. & Yamada, T. 1996. The impact of alcohol consumption and marijuana use on high school graduation. *Health Economics* 5 (1): 77-92.
- Zametkin, A.J.; Nordahl, T.E. & Gross, M. 1990. Cerebral glucose metabolism in adults with hyperactivity of childhood onset. *New England Journal of Medicine* 323:1361-366.